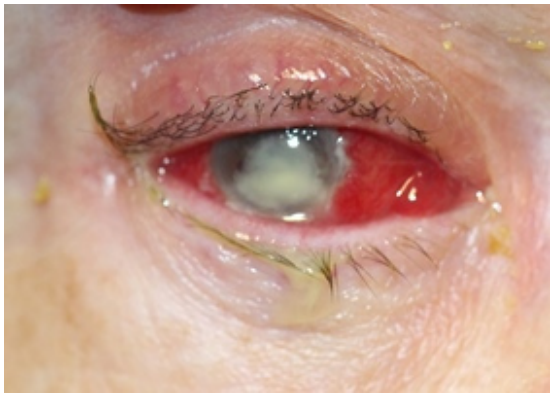

15. Endoftalmite/Panoftalmite

É uma inflamação, frequentemente de natureza purulenta, que afecta todos os tecidos (excepto a esclera).
Pós-operatória (aguda e tardia), endogena ou após traumatismo.
90% são gram + e 10% são gram -.
SINTOMAS: Fotofobia. Dor ligeira a moderada. Perda visão.
SINAIS: Quemose, olho vermelho, secreção mucopurulenta, edema córnea, edema palpebral, hipopion.

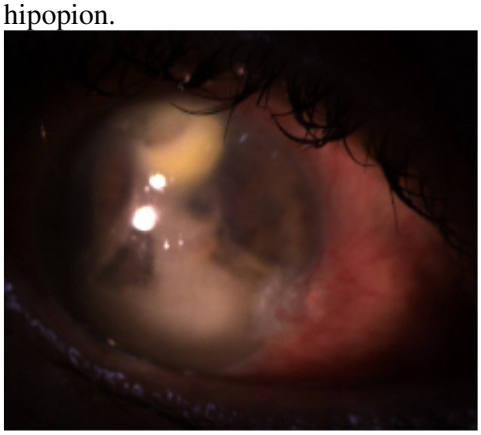
Fig. 15.1 Endoftalmite

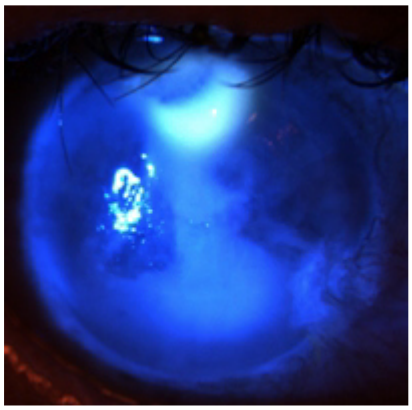
Fig. 15.2 Endoftalmite

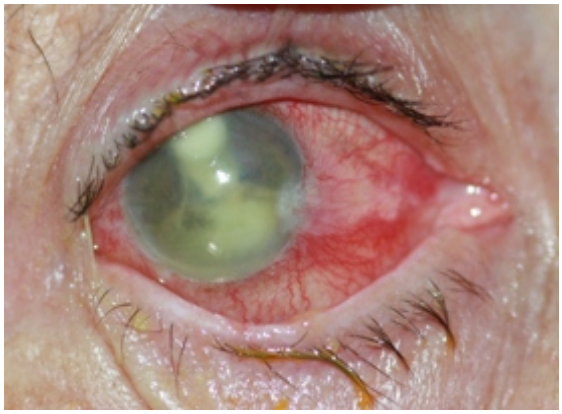
Fig. 15.3 Endoftalmite

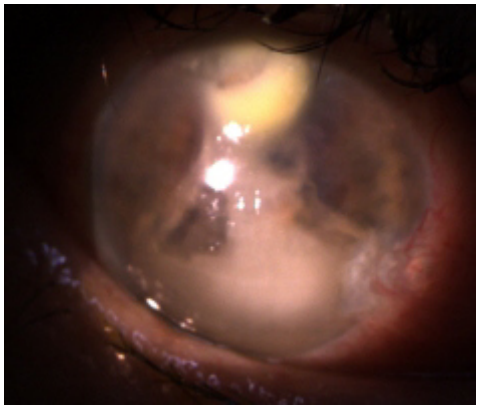
Fig. 15.4 Endoftalmite pós úlcera na córnea perfurada

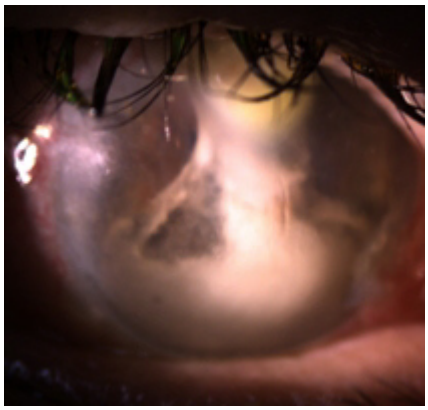
Fig. 15.5 Endoftalmite

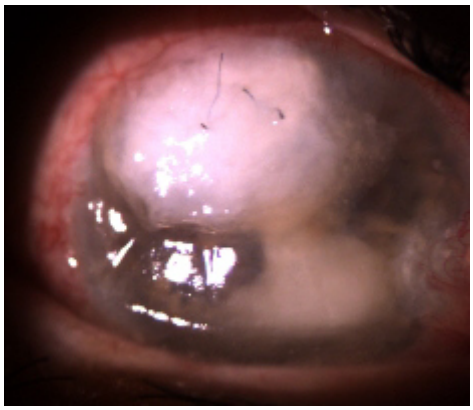
Fig. 15.6 Sutura de úlcera na córnea perfurada com cola fibrina

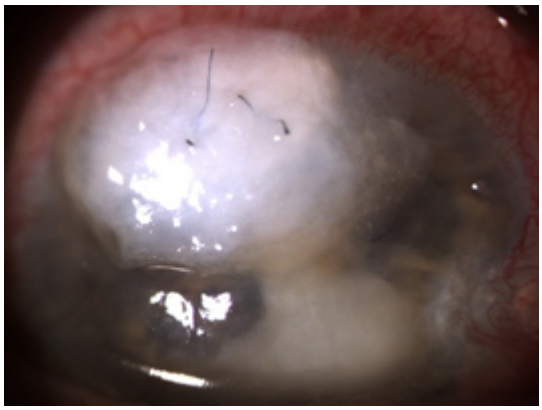

Fig. 15.7 Sutura de úlcera na córnea perfurada com cola Fibrina (pontos envolvendo a cola fibrina – técnica inédita)

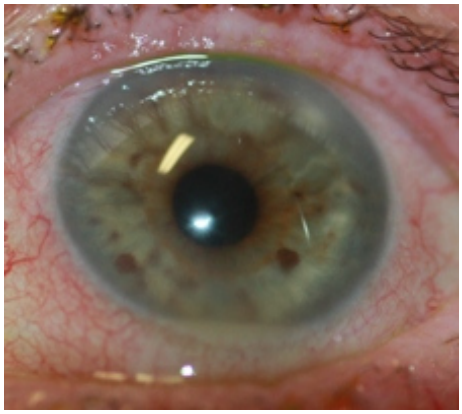

Fig. 15.8 Endoftalmite

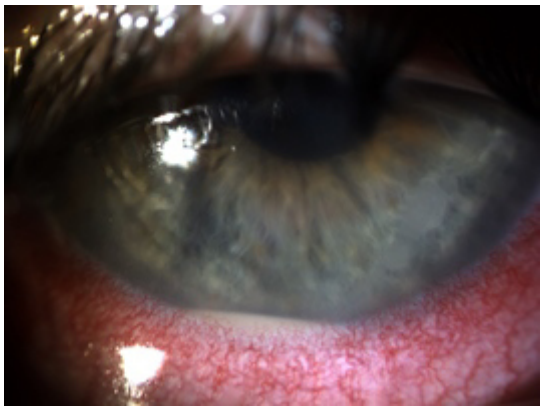

Fig. 15.9 Endoftalmite

PANOFTALMITE

Inflamação aguda e supurativa, com necrose da esclera e/ou córnea que leva á perfuração do globo ocular. Edema palpebral marcado.

Afecta todos os tecidos do globo ocular, habitualmente com extensão orbitaria. Quemose importante.

Mesmo controlada a infecção resulta em phtisis bulbi.

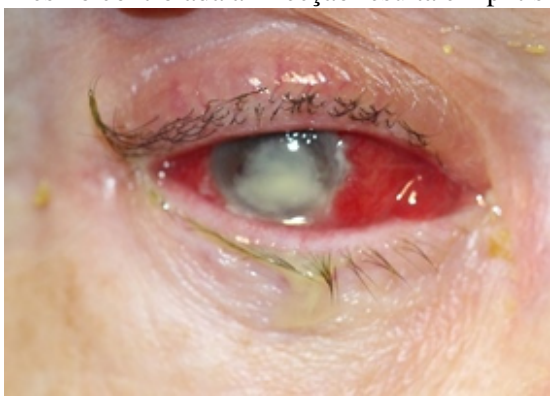

Fig. 15.10 Panoftalmite

Fig. 15.11 Panoftalmite